

## CASE REPORT

# Active immunisation against GnRH as treatment for unilateral granulosa theca cell tumour in mares

Daphne Behrendt<sup>1</sup> | Dominik Burger<sup>2</sup>  | Steffen Gremmes<sup>1</sup> | Katja Szunyog<sup>1</sup> |  
Selena Röthmeier<sup>1</sup> | Harald Sieme<sup>3</sup> 

<sup>1</sup>Equine Veterinary Hospital Jühnde, Jühnde, Germany

<sup>2</sup>Swiss Institute of Equine Medicine ISME, University of Berne, Agroscope, Avenches, Switzerland

<sup>3</sup>Unit for Reproductive Medicine – Clinic for Horses, University of Veterinary Medicine, Hannover, Germany

## Correspondence

Daphne Behrendt, Equine Veterinary Hospital Jühnde, Jühnde, Germany.  
Email: [daphne-behrendt@web.de](mailto:daphne-behrendt@web.de)

Harald Sieme, Unit for Reproductive Medicine – Clinic for Horses, University of Veterinary Medicine, Hannover, Germany.  
Email: [harald.sieme@tiho-hannover.de](mailto:harald.sieme@tiho-hannover.de)

## Abstract

**Background:** Stallion-like or aggressive behaviour in mares affected by unilateral granulosa theca cell tumour (GTCT) is well-known, but use of a GnRH-vaccine as an alternative to surgical removal of the neoplastic ovary has not been investigated.

**Objectives:** To determine the effect of immunisation against GnRH on ovarian size, testosterone concentration, Anti-Müllerian hormone (AMH) concentration, and owner-reported behaviour in four mares affected by unilateral GTCT.

**Study design:** Retrospective case report.

**Methods:** A presumptive diagnosis of GTCT was made in four mares based on clinical signs, behavioural changes, transrectal palpation, and ultrasonography. All mares were vaccinated twice with the GnRH-vaccine Improvac® on day 0 and on day 13–33. Further booster vaccinations were administered if aggressive behaviour recurred between days 15 and 498. Before and parallel to the vaccinations, serum levels of oestradiol, progesterone (P4), testosterone, and AMH were evaluated and transrectal ultrasonography was performed.

**Results:** In all horses, analysis of serum levels of oestradiol, progesterone, testosterone, and AMH confirmed the clinical diagnosis of GTCT. Serum levels of testosterone dropped to baseline levels following the first two of three vaccination in all mares. In addition, AMH serum values decreased shortly after the second vaccination in three of four mares, and in one of the four mares returned to baseline levels. No further GTCT linked behaviour was reported by the owners and the affected ovaries diminished in size in all four cases.

**Main limitations:** This report is a case series with a limited number of animals, no controls and no standardised immunisation protocol.

**Conclusions:** Repeated vaccinations with the GnRH-vaccine Improvac® mitigated owner-reported behavioural abnormalities and stopped tumour growth in four mares affected by unilateral GTCT over the entire observation period which extends to 7 years in one mare.

## KEYWORDS

horse, granulosa theca cell tumour, stallion-like behaviour, GnRH-vaccine

[Correction added on 08 January 2021 after first online publication: Harald Sieme was designated as corresponding Author]

This is an open access article under the terms of the [Creative Commons Attribution-NonCommercial-NoDerivs](https://creativecommons.org/licenses/by-nc-nd/4.0/) License, which permits use and distribution in any medium, provided the original work is properly cited, the use is non-commercial and no modifications or adaptations are made.

© 2020 The Authors. *Equine Veterinary Journal* published by John Wiley & Sons Ltd on behalf of EVJ Ltd

## 1 | INTRODUCTION

Granulosa cell tumours (GCT) and granulosa theca cell tumours (GTCT) are the most prevalent ovarian neoplasms in mares<sup>1</sup> and represent 2.5% of all equine tumours.<sup>2</sup> They contain primarily granulosa cells (GCT), or granulosa and theca cells (GTCT), respectively.<sup>1</sup> Usually they are benign, unilateral and slow growing.<sup>3,4</sup> Affected ovaries usually appear enlarged with a polycystic-honeycombed, rarely solid echogenic pattern or as a solid anechogenic cyst.<sup>5</sup> Contralateral ovaries are generally inactive and small.<sup>6</sup> Due to the increased dimension and weight, GCT and GTCT potentially lead to discomfort,<sup>7,8</sup> intra-abdominal bleeding, adhesions to the intestines and surrounding soft tissue,<sup>5</sup> and lameness.<sup>9</sup> Initially, the sexual behaviour of affected mares is altered, and at a later stage acyclic,<sup>6,10</sup> often accompanied by elevated serum testosterone levels and stallion-like behaviour (typically in GTCT cases).<sup>11,12</sup>

Support of diagnosis is generally made by laboratory analysis of serum levels of testosterone, progesterone, oestradiol, ir-inhibin, and Anti-Müllerian hormone (AMH).<sup>6,13</sup> The latter has recently gained importance because it is a sensitive parameter that becomes elevated in the initial stage of tumour growth.<sup>14</sup> In 95% of GCT and GTCT cases, the AMH levels are higher than 4 ng/mL.<sup>15</sup> Murase et al<sup>13</sup> reported cut-off values of 4.70 ng/mL for AMH and 1.65 ng/mL for ir-inhibin. These authors also claimed that AMH is more useful than ir-inhibin as a marker for diagnosis of equine GCT and GTCT. In most cases, unilateral ovariectomy is the first choice of therapy.<sup>6</sup> After surgical intervention, the contralateral ovary generally starts to re-show follicular activity<sup>12</sup> and mares can be used for breeding purposes.

GnRH-vaccines have been successfully evaluated as a temporary alternative to surgical castration of cryptorchid stallions<sup>16</sup> and normal male individuals.<sup>17</sup> In mares, it was possible to suppress the reproductive cycles using both the GnRH vaccines Improvac®<sup>18</sup> and Equity™.<sup>19</sup> GnRH-vaccines suppress ovarian activity by generating circulating antibodies that bind to endogenous GnRH. The bound endogenous GnRH is unable to bind to its receptor in the anterior pituitary leading to decreased secretion of FSH and LH. There are no previous published reports investigating GnRH-vaccines to treat equine GTCT.

The aim of this retrospective report was to evaluate whether riding and group pasturing of GTCT affected mares would again be possible after treatment with the GnRH-vaccine Improvac®. In addition, the influence of GnRH-vaccination on serum levels of testosterone and AMH as well as tumour growth were examined.

## 2 | METHODS

### 2.1 | Animals and experimental design

Four Warmblood mares resident on separate stud farms were included in the study. All mares had a history consistent with a unilateral GTCT, contralateral ovarian hypoplasia and behavioural problems that varied from stallion-like to aggressive behaviour. All owners had decided against surgical treatment of the tumours.

Case 1 was a maiden mare that was 13 years old at initial examination. The mare had recently become increasingly aggressive and showed stallion-like behaviour when in contact with other mares. Riding and pasturing with other horses had become impossible.

Case 2 was an 8-year-old multiparous mare that had been used for riding. She was presented because of stallion-like behaviour and riding was no longer possible.

Case 3, a 9-year-old multiparous mare, had stopped showing signs of oestrus and had become aggressive towards other horses.

Case 4, a 13-year-old maiden mare, was presented because of colic symptoms. At the time of initial examination, the mare had been with the owner for 1 year without showing any signs of oestrus and was behaving aggressively towards other horses.

After a general clinical examination, the uterus and ovaries of the mares were examined and recorded at various intervals by transrectal palpation and ultrasonography (Titan™, SonoSite) (Figure 1). The largest diameter of the ovaries measured in two perpendicular dimensions, as well as the number and location of ultrasonographically visible follicles were recorded. Using a B-mode ultrasonographic image, the cross-section of the enlarged ovary was classified into one of three categories (solid, multicystic, honeycomb) based on its sonographic structure.

At the time of writing, mare 1 had been observed by the authors for 7 years. Mare 2 was euthanised after 113 days of observation because of severe colic symptoms. Mare 3 had had been observed for 6 years, and mare 4 for one and a half years. All mares were examined by the same individual during the entire study.

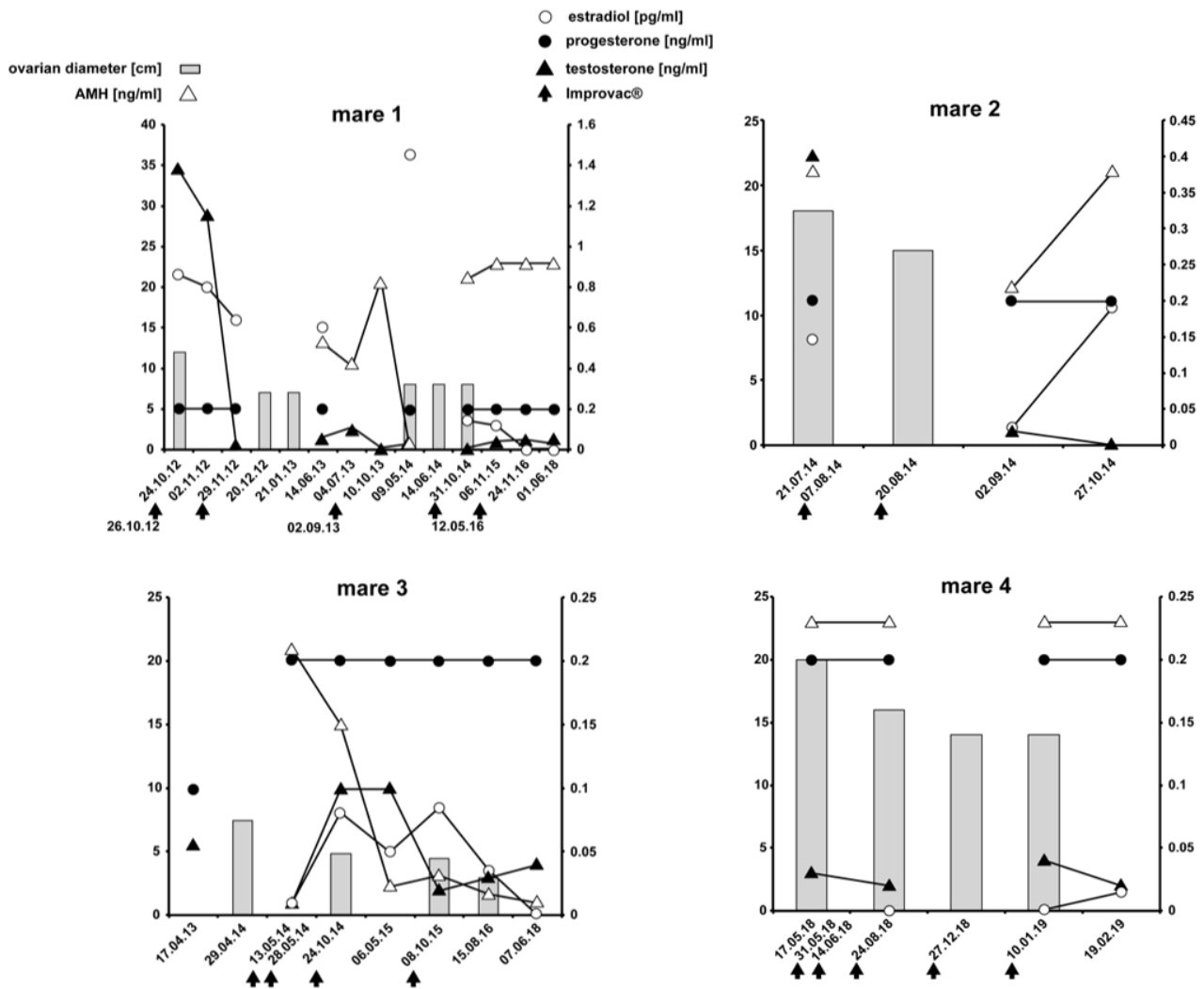
### 2.2 | GnRH immunisation

With the owners' consent, 1 mL Improvac® (200 mg GnRF-protein conjugate) (Improvac®, Zoetis) was injected into the left lateral cervical muscle (M. serratus ventralis cervicis) of each mare. One booster injection (1 mL) was administered 13–33 days after the primary vaccination. Follow-up vaccinations took place at variable intervals, ie when behavioural changes were observed by the owner again. Side effects of the vaccinations were recorded by the owner.

### 2.3 | Blood analysis

Blood samples were collected into tubes by venipuncture at the time of each clinical examination as shown in Figure 1. They were then centrifuged at 2000 g for 10 minutes. The supernatant serum was cooled to 5°C and shipped overnight to an accredited laboratory (LABOKLIN) for hormone analyses.

Serum concentrations of oestradiol (E, ng/mL), progesterone (P4, ng/mL), testosterone (T, ng/mL) and Anti-Müllerian hormone (AMH, ng/mL) were determined by ELISA according to the manufacturer's (LABOKLIN) instructions for use in equine serum samples. The intra- and interassay coefficients of variation for E, P4, T, and AMH



**FIGURE 1** Ovarian diameter, oestrogen, progesterone, testosterone and Anti-Müllerian hormone serum levels of (A) a 13-y-old maiden Warmblood mare (mare 1), (B) an 8-y-old pluriparous Hanoverian mare (mare 2), (C) a 9-y-old Hanoverian brood mare (mare 3), and (D) 13-y-old maiden mare (mare 4) after multiple vaccinations with the GnRH-vaccine Improvac®. (↑) indicates time of vaccination

concentrations were 5.7% and 7.3%, 4.2% and 3.0%, 4.8% and 3.3%, and 0.7% and 4.9%, respectively. The limit of sensitivity of the E, P4, T, and AMH assays were 1.4 pg/mL, 0.1, 0.01 and 0.01 ng/mL, respectively.

### 3 | RESULTS

The external physical exam including the genitalia and udder was clinically normal in all mares. Based on clinical observations, including unilateral enlarged ovary, contralateral ovarian hypoplasia, and stallion-like aggressive behaviour, the mares were diagnosed with unilateral GTCT. This was supported by elevated serum concentrations of AMH in all mares (Figure 1).

Three of the four mares also had elevated serum testosterone levels before vaccination (mare 1: 1.38 ng/mL, mare 2: 0.4 ng/mL, mare 3: 0.054 ng/mL). In all mares, testosterone serum levels decreased to baseline values (<0.05 ng/mL) after the first two

or three vaccinations (Figure 1). In addition, in three mares, AMH serum levels decreased shortly after the second vaccination, in one of them even to baseline levels (Figure 1C). In all mares and throughout the study, vaccination side effects that included stiffness of the neck and mild painful swelling in the area of injection were reported.

**Case 1:** Mare 1 no longer showed aggressive behaviour after the first booster vaccination. In addition, the affected ovary became smaller, contralateral ovarian hypoplasia did not change, and AMH levels decreased. After the third vaccination, AMH levels decreased to baseline levels and then increased again. This mare has been observed by us for 7 years now and during this time the affected ovary did not increase in size (Figure 1A).

**Case 2:** After the booster vaccination, mare 2 began to show typical mare behaviour again and the affected ovary had become smaller and the contralateral ovarian hypoplasia did not change (Figure 1B). However, she had to be euthanised after 4 months of observation because of unrelated medical issues (colic).

Case 3: The ovary of mare 3 decreased in size following the booster vaccination (Figure 1C). This mare has been observed for 6 years and the latest blood samples revealed basal AMH levels, ie less than the GCT/GTCT-indicative value of  $>4.7$  ng/mL.<sup>13</sup> Both ovaries showed hypoplasia. According to the owner, the mare showed normal oestrus and no abnormal behaviour 1 year after the last vaccination that had been carried out 4 years ago.

Case 4: After the first vaccination, mare 4 showed considerably less aggression towards other horses and it was possible to ride the mare again. After having been introduced to a new herd, she even showed normal oestrus behaviour (this had been absent over the last year). The ultrasonographical examination revealed that the affected ovary was smaller and more compact than at the beginning of the study. The size of the contralateral ovary was  $4 \times 5$  cm (Figure 1D).

## 4 | DISCUSSION

In this case report we investigated the efficacy of the GnRH-vaccine Improvac® for resolution of undesired behaviour in mares diagnosed with a unilateral GTCT tumour. For different reasons, surgical treatment of the mares was not an option. Due to a lack of other therapeutic options, the off-label use of a GnRH-vaccine was considered justifiable. Our results show that owner-reported behavioural abnormalities that were considered to be difficult to cope with decreased after immunisation with the GnRH-vaccine Improvac®.

After the second vaccination (first booster), there were no further reports of stallion-like and aggressive behaviour in any of the mares. Further follow-up examinations were made after abnormal behaviour had reappeared. Subsequent vaccinations led to the disappearance of recurring undesired behaviour, regardless of whether the monitored hormone levels decreased or remained constant.

Our findings are in agreement with results described in a study by Imboden et al.<sup>18</sup> In their study, the amount of GnRH antibodies did not correlate with the length or quality of suppression of ovarian activity. Immediately after the first vaccination, a rise of GnRH antibody levels occurred, reaching its peak 2-3 weeks after the booster vaccination at day 30. The period between vaccination and interruption of ovarian activity was variable, although it never took longer than 8 weeks. Consequently, in all mares, a suppression of ovarian activity could be observed. In five of nine mares, this suppression occurred at different points of time within a window of 100 weeks, the shortest period being 23 weeks. In stallions, it also has been shown that antibody levels do not reflect observed sexual behaviour and spermatological parameters.<sup>20</sup> The literature supports age as associated with variation in GnRH antibodies.<sup>21</sup> Genetic factors and individual immune responses might be responsible for the variable amount of GnRH antibodies needed to suppress ovarian activity effectively.<sup>22</sup> A comparable rise of GnRH antibody levels has been reported when the GnRH-vaccine Equity™ was used to vaccinate mares. Dimensions and follicular activity of both ovaries were also clearly reduced.<sup>19</sup> This study also found that the duration of ovarian

activity suppression was variable and lasted for at least 3 months.<sup>19</sup> In another study, 31 horses (21 mares, 10 stallions) were vaccinated with Equity™ twice at 4-week intervals to influence undesired sexual behaviour. In 84% of cases, a decrease of the unwanted behaviour could be observed by the owners.<sup>23</sup>

In a study investigating the effects of Equity™ in 61 mares, normal reproductive cycles resumed in 98% of the vaccinated mares within 2 years of the last vaccination.<sup>24</sup> Similarly, in a study investigating 51 mares vaccinated with Improvac®, a resumption of cyclic activity was observed in 92.2% of cases within 650 days with a mean interval of 418 days.<sup>21</sup> However, in another study, 6 of 16 mares had no onset of ovarian activity within the observation period of 30-34 months.<sup>19</sup> Therefore, it is possible that an irreversible impairment of the hypothalamic-pituitary-gonadal axis might occur in some mares,<sup>18,20,21</sup> especially if they are young and vaccinated multiple times (personal observation). This observation might be favourable when using GnRH vaccines to treat GTCT tumours in mares. However, more standardised studies investigating the long-term effects of multiple GnRH-vaccinations in mares are required.

Change of reported behaviour and the suspension of tumour growth or even reduction of ovarian dimension following vaccination indicate that the GTCT depends on the presence of GnRH. Zelli et al.<sup>25</sup> found no differences in the pituitary responsiveness to an exogenous GnRH stimulus either before or after GTCT removal in eight mares when compared to four healthy mares. In our study, two mechanisms following GnRH vaccination appear to be likely: (a) an indirect pathway that suppresses gonadotropins and endogenous steroids, and (b) a direct pathway that uses local mechanisms that act through specific receptors expressed by the tumour.<sup>26</sup> A consistent decrease of serum AMH levels has not been observed in most of our samples, except for mare 3. Therefore, the effect of GnRH immunisation on expression of AMH by the granulosa-like cells of the tumour remains to be investigated.

As the use of Equity™ (approved in New Zealand and Australia by Pfizer Animal Health, Australia for oestrus suppression and treatment of oestrus associated behavioural abnormalities in mares) is not permitted in Europe, we had to use the vaccine Improvac® which is licensed for use in pigs. Imboden et al.<sup>18</sup> describe severe side effects when a dose of 400 mg GnRF-protein conjugate is injected into one site in the horse. Two horses vaccinated with that dosage (and at the same site) were even reported to have suffered from anaphylactic shock and consequently died.<sup>27</sup> In contrast with Improvac®, Equity™ seems to cause less frequent and severe side effects.<sup>17,20</sup> Based on personal field observations regarding the efficiency and side effects of Improvac®, we adapted the injected dosage to the one of Equity™, ie 200 mg GnRH-protein conjugate. Indeed, the owners of the mares did not observe any severe side effects following injection with Improvac® at this dose, and at the same injection site as in Imboden et al.<sup>18</sup> The reduced tolerance to Improvac® compared to Equity™ may be due to use of different adjuvants and a different carrier protein. Side effects linked to the dosage of Improvac® and the optimal injection site remain to be investigated.

Limitations of this case study are the absence of an untreated control group and standardised approach ie the vaccination protocol and frequency. Indeed, not all untreated GTCT show growth, and may remain stable and unchanged over years, or may fluctuate in size, as can hormone levels.<sup>1</sup> In addition, no standardised behavioural scoring was used, and the owner-based assessment of changes in behaviour might be biased.

A further limitation of the use of GnRH vaccination exists in competing sport horses. While the procedure is currently permitted for events under the regulation of the FEI (Fédération Equestre Internationale), the International Federation of Horseracing Authorities (IFHA) bans immunisation against GnRH in racehorses.<sup>28</sup>

## 5 | CONCLUSIONS

Overall, our case study in four mares affected by a unilateral GTCT and where the owners decided against surgical therapy supports our hypothesis that GnRH immunisation reduces or eliminates behavioural abnormalities and stops tumour growth. However, more investigations are indicated because there are considerable risks to not removing a GTCT, such as growth, bleeding and adhesions. When using a GnRH vaccination protocol we recommend monitoring effects and tumour evolution, as in untreated mares, until there is more evidence that GnRH vaccination is universally effective and helpful.

## ACKNOWLEDGEMENTS

We acknowledge the collaboration of horse owners for communication of their observations and use of the clinical data in research, and Shannon Axiak for precious support. Open access funding enabled and organized by Projekt DEAL.

## CONFLICT OF INTERESTS

No competing interests have been declared.

## AUTHOR CONTRIBUTIONS

D. Behrendt and S. Gremmes designed the study, performed the experiments, contributed to data analysis and interpretation, and prepared the manuscript. K. Szunyog and S. Röthmeier contributed to experimentations. D. Burger contributed to data analysis and interpretation, and preparation of the manuscript. H. Sieme contributed to study design, data analysis and interpretation, and preparation of the manuscript. All authors gave their final approval for the manuscript.

## ETHICAL ANIMAL RESEARCH

Research ethics committee oversight not required: retrospective study of clinical records.

## OWNER INFORMED CONSENT

Explicit owner informed consent for inclusion of animals in this study was not stated.

## DATA ACCESSIBILITY STATEMENT

The data that support the findings of this study are available from the corresponding author upon reasonable request.

## ORCID

Dominik Burger  <https://orcid.org/0000-0003-0834-5161>

Harald Sieme  <https://orcid.org/0000-0001-9658-8790>

## REFERENCES

- McCue PM, Roser JF, Munro CJ, Liu IKM, Lalsey BL. Granulosa cell tumours of the equine ovary. *Vet Clin North Am Equine Pract.* 2006;22:799–817.
- Sundberg JP, Burnstein T, Page EH, Kirkham WW. Neoplasm of equidae. *J Am Vet Med Assoc.* 1977;170:150–512.
- Frederico LM, Gerard MP, Pinto CRF, Gradil CM. Bilateral occurrence of granulosa-theca cell tumours in an Arabian mare. *Canadian Vet J.* 2007;48:502–5.
- Turner TA, Manno M. Bilateral Granulosa cell tumor in a mare. *J Am Vet Med Assoc.* 1983;182:713–4.
- Rambags BP, Stout TA, Rijkenhuizen ABM. Ovarian granulosa cell tumours adherent to other abdominal organs: surgical removal from 2 warmblood mares. *Equine Vet J.* 2003;35:627–32.
- McCue PM. Equine granulosa cell tumours. *Proc Am Ass Equine Practns.* 1992;38:587–93.
- Van der Zaag EJ, Rijkenhuizen AB, Kalsbeek HC, Peperkamp NH. A mare with colic caused by an ovarian tumour. *Vet Q.* 1996;18:60–2.
- Sedrish SA, McClure JR, Pinzo C, Oliver J, Burba DJ. Ovarian torsion associated with granulosa-theca cell tumour in a mare. *J Am Vet Med Assoc.* 1997;211:1152–4.
- Gift LJ, Gaughan EM, Schöning P. Metastatic granulosa cell tumour in a mare. *J Am Vet Med Assoc.* 1992;200:1525–6.
- Meagher DM, Wheat JD, Hughes JP, Stabenfeldt GH, Harris BA. Granulosa cell tumours in mares a review of 78 cases. *Proc Am Ass Equine Practns.* 1977;23:133–43.
- Crabtree J. Review of seven cases of granulosa cell tumour of the equine ovary. *Vet Rec.* 2011;169:251.
- Stabenfeldt GH, Hughes JP, Kennedy PC, Meagher DM, Neely DP. Clinical findings, pathological changes and endocrinological secretory patterns in mares with ovarian tumours. *J Reprod Fertil Suppl.* 1979;27:277–85.
- Murase H, Ball BA, Tangyuenyong S, Watanabe G, Sato F, Hada T, et al. Serum Anti-Müllerian hormone concentrations in mares with Granulosa Cell Tumours versus other ovarian abnormalities. *J Equine Vet Sci.* 2018;60:6–10.
- Almeida J, Ball BA, Conley AJ, Place NJ, Liu IKM, Scholtz EL, et al. Biological and clinical significance of anti-Müllerian hormone determination in blood serum of the mare. *Theriogenology.* 2011;76:1393–403.
- Ball BA, Almeida J, Conley AJ. Determination of serum anti-Müllerian hormone concentrations for the diagnosis of granulosa-cell tumours in mares. *Equine Vet J.* 2013;45:199–203.
- Schanbacher BD, Pratt BR. Response of a cryptorchid stallion to vaccination against luteinising hormone releasing hormone. *Vet Rec.* 1985;116:74–5.
- Janett F, Stump R, Burger D, Thun R. Suppression of testicular function and sexual behaviour by vaccination against GnRH (Equity™) in the adult stallion. *Anim Reprod Sci.* 2009;115:88–102.
- Imboden I, Janett F, Burger D, Crowe MA, Hässig M, Thun R. Influence of immunization against GnRH on reproductive cyclicity and estrous behavior in the mare. *Theriogenology.* 2006;66:1866–75.



19. Elhay M, Newbold A, Britton A, Turley P, Dowsett K, Walker J. Suppression of behavioural and physiological oestrus in the mare by vaccination against GnRH. *Aust Vet J.* 2007;85:39–45.
20. Burger D, Janett F, Vidament M, Stump R, Fortier G, Imboden I, et al. Immunization against GnRH in adult stallions: effects on semen characteristics, behaviour and shedding of equine arteritis virus. *Anim Reprod Sci.* 2006;94:107–11.
21. Schulman ML, Botha AE, Muenscher SB, Annandale CH, Guthrie AJ, Bertschinger HJ. Reversibility of the effects of GnRH-vaccination used to suppress reproductive function in mares. *Equine Vet J.* 2013;45(1):111–3.
22. Keeling BJ, Crighton DB. Reversibility of the effects of active immunization against LH-RH. In: Grighton DB, editor. *Immunological Aspects of Reproduction in Mammals.* London: Butterworths; 1984. p. 379–97.
23. Wenzinger B, Kähn W, Bleul U. The use of a GnRH-vaccine in mares and stallions to influence undesirable behavior: a retrospective study of 31 cases. *Schweiz Arch Tierh.* 2010;152(8):373–7.
24. Card C, Raz T, LeHeiget R, Sibert G. GnRH Immunization in mares: ovarian function, return to cycling, and fertility. *P. Annu. Conv. Am. Equin - Orlando, Florida,* 2007. p. 576–7.
25. Zelli R, Sylla L, Monaci M, Stradaoli G, Sibley LE, Roser JF, et al. Gonadotropin secretion and pituitary responsiveness to GnRH in mares with granulosa-theca cell tumour. *Theriogenology.* 2006;66:1210–8.
26. Kim HJ, Lee SC, Bae SB, Kwon KW, Kim CK, Lee NS, et al. GnRH agonist therapy in a patient with recurrent ovarian granulosa cell tumours. *J Korean Med Sci.* 2009;24:535–8.
27. Burger D, Vidament M, Janett F, Sieme H, Dobretsberger M, Thun R. Immunization against GnRH in horses with Improvac and Equity: indications, short and long time effects, perspectives. *Proc ICERM Leipzig Vet Conf,* 978-3-86583-441-6. 2010; pp. 326–9.
28. Article 6A, Prohibited substances. International Agreement on Breeding, Racing and Wagering (IABRW), International Federation of Horseracing Authorities (IFHA). <http://www.horseracingintfed.com/resources/2016Agreement.pdf>. (Accessed 15 December 2016).


**How to cite this article:** Behrendt D, Burger D, Gremmes S, Szunyog K, Röthemeier S, Sieme H. Active immunisation against GnRH as treatment for unilateral granulosa theca cell tumour in mares. *Equine Vet J.* 2021;53:740–745. <https://doi.org/10.1111/evj.13352>

# Broodmare Reproduction for the Equine Practitioner

**Author: William B. Ley**

Publisher: Teton NewMedia May 2004  
Spiralbound 250 pages.

A concise and liberally illustrated working guide on broodmare health and breeding management for veterinarians, veterinary students and breeders. The presentation includes all of the clinical procedures and assessments necessary for maintaining the health and breeding soundness of the broodmare. This handy reference covers the use of ultrasonography for diagnosis and monitoring of the mare, cytologic studies essential to diagnosis, normal and abnormal reproductive anatomy, culturing techniques for infections, diseases affecting the reproductive capacity of the broodmare and detailed guidelines for effective breeding. It provides detailed protocols for vaccination and management of important reproductive diseases and disorders. The practical presentation includes thorough guidelines for the Breeding Soundness Examination. All aspects of assisted reproduction (embryo transfer, follicular aspiration, and oocyte collection) are evaluated and step-by-step procedures are provided.



**BEVA Member: £45.35**  
**Non Member: £55.99**

*William B. Ley, DVM, MS, DACT*

**BEVA Bookshop**  
[www.beva.org.uk](http://www.beva.org.uk) • 01638 723555 • [bookshop@evj.co.uk](mailto:bookshop@evj.co.uk)